

Using of a bacteriostatic PVA foam to inhibit growth of MRSA and VRE in deep soft tissue infected wounds in one long term care facility

By: **Mary Webb**, RN, BSN, MA CIC, Infection Control Practitioner, San Mateo Medical Center, County of San Mateo, San Mateo, California

Introduction

Wounds frequently become colonized or even infected. Use of a bacteriostatic foam composed of polyvinyl (PVA) with Methylene Blue and Gentian Violet (two organic pigments – complexed) inhibit the growth of bacteria and microorganisms including MRSA and VRE while removing exudate from the wound bed.

Objective

To treat deep soft tissue infected wounds in conjunction with NPWT on three different wounds.

Method

This case series describes the use of a bacteriostatic foam composed of polyvinyl alcohol (PVA) with Methylene blue and Gentian Violet in conjunction with negative pressure wound therapy (NPWT) to control or remove infection in three residents who were admitted to LTC for ongoing wound care. Each resident had many comorbidities. All wounds were contaminated with MRSA. Following surgical debridement to clear away any frank infection, PVA foam impregnated with Methylene Blue and Gentian Violet was placed over the wound and covered with NPWT. Dressing changes were three times a week. The PVA foam provided a non-adherent covering and maintained a moist wound health environment.

Conclusions

Despite co-morbidities, the wound care team was able to effectively progress wounds toward closure without infection and without the need of further surgical intervention.

Results

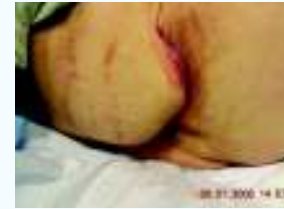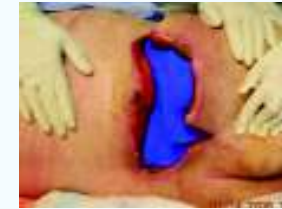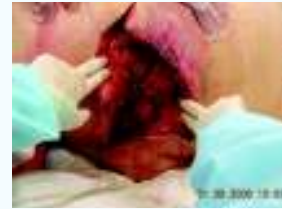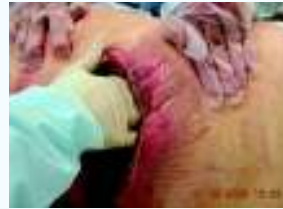The combination of bacteriostatic PVA foam and NPWT allowed for full wound healing, decreased pain with dressing changes and improve patient comfort between dressing changes.

Sponsored by:

Hydrofera
Pioneering Advancements in PVA Technology

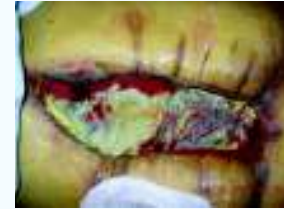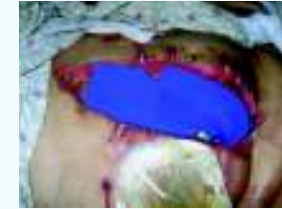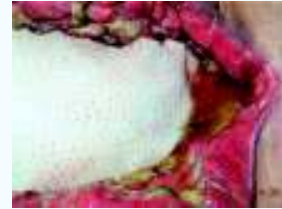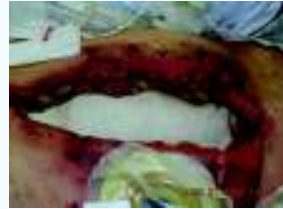
Case 1

A 56 year-old male who resides in a locked psychiatric facility presented to ER with change in mental status, BP 70/30, WBC 40.40, DM, and presumed septic. On day two of admission a rapidly increasing cellulitis was observed on the back, extending to the flank, down the hip and lateral thigh. Aggressive surgical intervention identified multiple abscesses, tracking down to muscle, through the flank expressing copious pus.



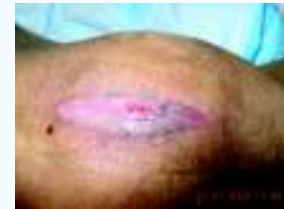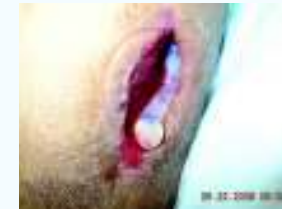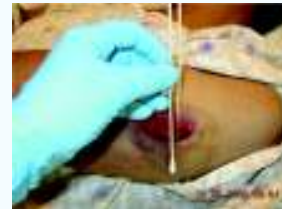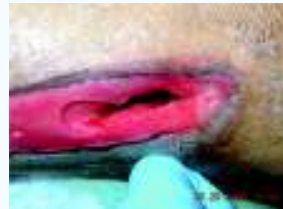Case 2

57 year old admitted for small bowel obstruction. Medical history includes DMII, past heavy alcohol and smoking use. Upon opening the abdomen, cirrhosis of the liver, large quantity of ascetic fluid, small bowel contents, metastatic cancer and intra abdominal sepsis was found. Considerable granulation made it impossible to close the surgical site by primary intention. Porcine mesh was selected to cover the abdominal contents.



Case 3

48 year old male admitted with multiple abscesses, left and right upper arm, right thigh, calf and knee. Medical history includes DMII, heavy alcohol, smoking use and substance abuse. Aggressive surgical intervention debrided the multiple abscesses.



Bacteriostatic Wound Dressings – When Managing Bioburden is a Priority.

Bacteriostatic Protection

- Provides a protective bacteriostatic cover that may help prevent infection
- Manages bioburden, which helps the body's own immune system restore bacterial balance
- Broad spectrum activity against microorganisms commonly found in wounds, including MRSA and VRE
- Agents (Gentian Violet and Methylene Blue) are bound to the dressing to inhibit the growth of microorganisms
- Physically binds harmful endotoxins which can aid in patient comfort

Highly Absorptive

- Pulls bacteria-laden exudate up and away from the wound which may facilitate healing and aid in patient comfort
- Maintains similar or superior absorbency as compared to other highly absorptive dressings
- When used with an appropriate cover dressing, creates a moist wound environment which may aid in wound healing